

---

# Ocular complications in pre-eclampsia

Dian Nadia Abu Talib<sup>1</sup>, Wahidah Wagimon<sup>2</sup>, Ainal Adlin Naffi<sup>1</sup>, Rona Asnida Nasaruddin<sup>1</sup>, Jemaima Che-Hamzah<sup>1</sup>, Mohd Hashim Omar<sup>2</sup>, Norshamsiah Md Din<sup>1</sup>

<sup>1</sup>Department of Ophthalmology, Universiti Kebangsaan Malaysia Medical Centre, Cheras, Kuala Lumpur, Malaysia; <sup>2</sup>Department of Obstetrics and Gynecology, Universiti Kebangsaan Malaysia Medical Centre, Jalan Yaacob Latif, 56000 Cheras, Kuala Lumpur, Malaysia.

## Abstract

Exudative retinal detachment (ERD) is a rare complication of pre-eclampsia in pregnancy. The pathophysiology is uncertain but it is thought to be due to micro-vasculopathy involving the choroidal circulation. We report a case of a 36-year-old woman with underlying essential hypertension complicated with impending eclampsia in her third trimester of pregnancy. She developed bilateral bullous ERD at 34 weeks of gestation. Following emergency caesarean section, her blood pressure normalised after 10 days and the ERD partially resolved spontaneously after 30 days. Her best-corrected visual acuity improved from hand movement (HM) in the right eye and counting finger (CF) in the left eye to 6/24 bilaterally after 30 days postpartum. Pre-eclampsia-induced ERD is usually managed conservatively and the prognosis is usually good.

*Keywords:* exudative retinal detachment, impending eclampsia, pregnancy, hypertension

# Komplikasi okular pada pra-eklampsia

## Abstrak

Lekang retina eksudatif (ERD) adalah komplikasi pra-eklampsia yang jarang berlaku semasa kehamilan. Patofisiologi tidak begitu jelas tetapi dianggap disebabkan oleh mikrovaskulopati yang terjadi kepada salurdarah jaringan koroidal. Kami melaporkan kes seorang wanita berusia 36 tahun yang berlatarbelakangkan penyakit tekanan darah tinggi yang kemudiannya dirumitkan dengan komplikasi eklampsia yang berlaku dalam trimester ketiga kehamilannya. Beliau mengalami ERD bullous pada kedua belah mata pada minggu 34 kehamilan. Selepas pembedahan secara caesarean tekanan darahnya turun ketahap normal selepas 10 hari dan ERD sembuh secara spontan selepas 30 hari. Ketajaman penglihatannya berubah dari pergerakan tangan (HM) sahaja di mata kanan dan mengira jari (CF) di mata kiri kepada 6/24 pada kedua-dua belah mata pada hari ke 30 selepas bersalin. ERD yang disebabkan oleh pra-eklampsia biasanya dirawat secara konservatif dan prognosis biasanya baik.

*Kata kunci:* hipertensi, kehamilan, lekang retina eksudatif, pra-eklampsia

## Introduction

Hypertensive disorder is one of the commonest medical complications of pregnancy. In Southeast Asia, hypertensive disorders accounted for 14.5 % of maternal deaths, whereas in the Caribbean and Latin America, the figure was over 22.1%.<sup>1</sup>

Systemic hypertension is related to a variety of ocular presentations. This includes the four grades of hypertensive retinopathy, retinal vein occlusions, and ischaemic optic neuropathies. The occurrence of ERD with uncontrolled hypertension in pregnancy from pre-eclampsia poses additional complications unique to this situation, possibly due to microvasculopathy affecting the choroidal vasculature, similar to microvascular complications in the kidney resulting in albuminuria. We present an uncommon case of hypertensive chorioretinopathy with bilateral ERD secondary to impending eclampsia in pregnancy.

## Case report

A 38-year-old gravida 3 para 2 woman was diagnosed with essential hypertension at 11 weeks of gestation during her routine antenatal checkup. She was started on T. methyldopa 200 mg TDS to optimize her blood pressure (BP) at 31 weeks' gestation.

At 34 weeks of gestation, she was admitted for impending eclampsia with a BP of 170/110 mmHg and proteinuria. She presented with headache and generalized blurring of vision bilaterally for one day prior to admission but there were no flashes of lights, floaters, or visual field defect. However, visual acuity was not measured during admission. Biochemistry markers did not suggest HELLP syndrome (haemolysis, elevated liver enzymes, and low platelet level). Intravenous magnesium sulphate and intravenous labetalol were administered, and she underwent an emergency caesarean section on the same day for impending eclampsia.

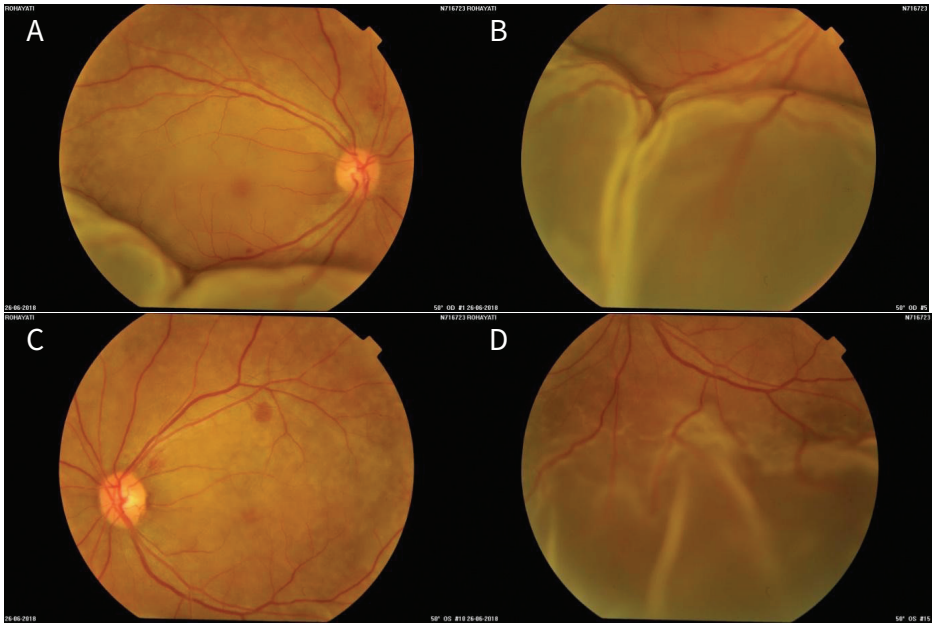
At postnatal day 1, her BP was better controlled, but her visual acuity worsened to hand movement (HM) in the right eye (OD) and counting finger (CF) at one foot in the left eye (OS). The relative afferent pupillary defect was absent. Anterior segment examination of the eyes was normal with no evidence of inflammation. Fundus examination revealed bilateral bullous ERD inferiorly involving the macula with widespread choroidopathy and scattered retinal haemorrhages at the supero-nasal and supero-temporal quadrants of the optic disc and at the macula in OS. (Fig. 1A-D). The shifting fluid test was positive, confirming the suspicion of ERD. There was no retinal break found clinically. The patient's BP normalized over ten days, her visual acuity gradually improved over one month, and serial fundus examination showed slow resorption of subretinal fluid (SRF). Her vision at one-month postpartum was 6/24 bilaterally with some residual SRF (Figs. 2 and 3). At 3 months follow-up, her best-corrected vision acuity was 6/12 OD and 6/9 OS, with total resorption of SRF and resolving retinal haemorrhages with irregularities over retinal pigment epithelium (RPE) and inner segment and outer segment (IS/OS) disruptions. Her BP was well controlled only by oral amlodipine 5 mg once daily.

## Discussion

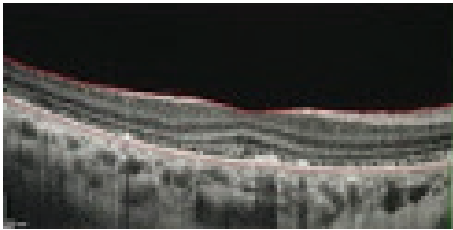
Accelerated systemic hypertension may result in various complications to the eye causing considerable amount of visual loss. This includes non-ocular complications such as cerebral infarction or haemorrhage, and complications pertaining to the vasculature in the eye, such as ischemic optic neuropathy and retinal vascular occlusions.<sup>2</sup> A more uncommon cause of visual loss as demonstrated in our case is ERD.

ERD is a rare complication of pre-eclampsia, which has only been reported in 1-2% of preeclampsia cases.<sup>3</sup> Typically, it is completely reversible depending on the degree of RPE ischemia seen in severe pre-eclampsia. Subretinal fibrosis or epiretinal membrane may follow as a later complication.

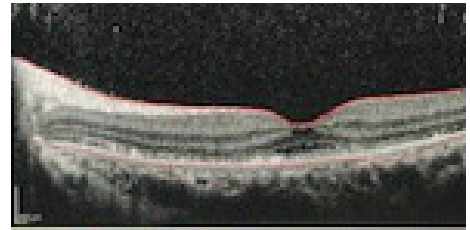
The pathophysiology of ERD in pre-eclampsia is not well understood and controversial. The passive and active transport mechanism within RPE and ocular forces within the eye are important to maintain a unidirectional flow from vitreous to the choroid. Passive transport mechanisms include intraocular pressure and



*Fig. 1.* Fundus photographs of both eyes. (A) Widespread whitening of the choroidal area indicating choroidopathy with flame-shaped haemorrhages seen at the major vascular arcades in OD. (B) Inferior bullous retinal detachment extending to the inferior vascular arcades and the macula involving the OD. (C) Similar changes of choroidal whitening at the posterior pole in the OS. The macula is also shallowly detached, indicated by striations on the macula. (D) ERD seen mainly inferior to the vascular arcades in OS.



*Fig. 2.* OD OCT at one month revealed residual hyper-reflective, fibrinous SRF.



*Fig. 3.* OS OCT at one month showing similar features as OD.

osmotic pressure from the choroid. Disruption in one of these two mechanisms will result in increased fluid in the subretinal space.<sup>4</sup>

ERD is thought to occur from microvascular occlusion of the choroidal vasculature. Intense vasoconstriction of the choroidal vessels leads to fibrinoid necrosis or thrombosis of the choroidal vessels. This results in choroidal ischemia and subsequently increased vascular permeability as well as reduced ability to accommodate extra fluid<sup>5</sup> as the hypoxic drive releases vascular endothelial growth factor (VEGF), leading to increased permeability and disruption of endothelial junctions.<sup>6</sup> The ensuing ischemia of the overlying RPE disrupts RPE function and its tight junctions, which form the blood-retinal barrier.<sup>5</sup> The subsequent accumulation of fluid into the potential space between the neurosensory retina and the RPE results in ERD and areas of choroidal hypo- and non-perfusion manifested as Elschnig spots.<sup>7</sup>

As an alternative to the vasospasm theory, it is suggested that hyperperfusion and breakthrough in autoregulation of orbital vessels will further increase the permeability of retinal and choroidal arterioles, causing retinal oedema and serous detachment.<sup>8</sup>

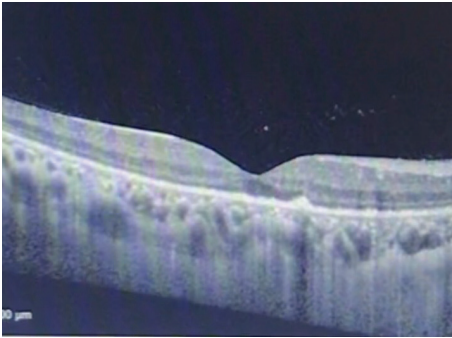
Choroidal blood flow depends on the vascular resistance between the arterial input and venous output and on the arterial and venous pressure difference. The mean choroidal blood flow ( $ChBF_m$ ) is as stated below in Formula 1,

$$ChBF_m = \frac{(MOAP - IOP)}{R_m} = \frac{PP_m}{R_m} \quad \text{Formula 1}$$

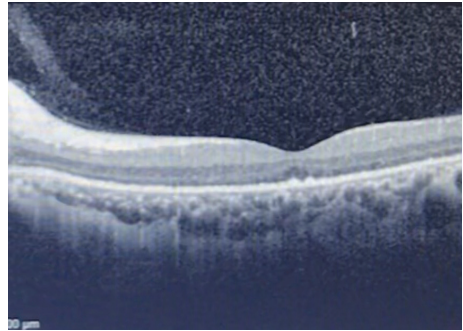
where  $MOAP$  is the mean ophthalmic artery blood, which for a sitting subject is approximately  $2/3(BP_{diastolic} + 1/3(BP_{systolic} - BP_{diastolic}))$ .  $R_m$  is the average resistance during the heart cycle.  $PP_m$  is commonly defined as the mean ocular perfusion pressure.<sup>9</sup> With reference to Formula 1, it is postulated that relative hypotension episodes that occur immediately post-delivery will further compromise the choroidal blood flow and worsen accumulation of fluid in the subretinal space, thus explaining the postpartum worsening of the patient's vision.

Management of hypertensive ERD mainly involves stabilization of BP. Normalization of BP postpartum results in the return of the RPE blood supply and function. With resorption of SRF and reattachment of the RPE and neurosensory retina, ERD usually resolves spontaneously within a few weeks with the return of normal vascular and metabolic support for the photoreceptors.<sup>10</sup> The visual prognosis is usually good, with vision returning in a few weeks. However, in our patient there was some residual visual acuity impairment likely explained by her optical coherence tomography (OCT) result, which showed segmented area of RPE irregularities with IS/OS disruptions (Figs. 4 and 5).

In this anti-VEGF era, more studies are looking into its role as an adjunct treatment in ERD due to elevated ocular VEGF levels. Kim *et al.* suggested intravitreal bevacizumab injection might be an effective therapeutic modality for treating



*Fig. 4.* OD OCT at three months revealed RPE irregularities with IS/OS disruptions.



*Fig. 5.* OS OCT at three months revealed RPE irregularities with less severe IS/OS disruptions compared to OD.

exudative hypertensive retinopathy.<sup>11</sup> The study is limited by the small number of patients and the lack of a control group.

However, administering medication during pregnancy or breastfeeding remains a challenge due to the paucity of published information on intravitreal injections during pregnancy and breastfeeding. One study reported undetectable levels of bevacizumab in the breast milk of nursing mothers who were treated with monthly injections after delivery.<sup>12</sup> However, there are no studies on the penetration of ranibizumab or aflibercept into breast milk.

Treatment should only be administered following a thorough discussion with the patient and informed consent, as well as consultation with an obstetrician. Of the currently available anti-VEGF agents, ranibizumab may be the safest choice as it has been shown to have the most rapid clearance from systemic circulation and weakest effect on plasma VEGF levels.<sup>13</sup> Breastfeeding is likely not a contraindication to anti-VEGF therapy. It should be noted that these recommendations are based on the sparse literature that explores this issue and decisions should only be made after taking into consideration risks and benefits for both mother and baby. Furthermore, in hypertensive choroidoretinopathy, the causes of elevated VEGF are transient and reversible after normalization of BP. Thus, in most cases, a more conservative approach is taken.

## Conclusion

Most ERD secondary to hypertensive retinopathy resolves spontaneously. Visual prognosis is good unless there is irreversible ischemic RPE in severe eclampsia. It is therefore important to identify those at risk and to have good BP control and timely delivery for the best outcome of both mother and baby.

## References

1. Say L, Chou D, Gemmill A, et al. Global causes of maternal death: A WHO systematic analysis. *Lancet Glob Health*. 2014;2(6):e323-333.
2. Villalba-Pinto L, Hernández-Ortega MÁ, Lavid De Los Mozos FJ, et al. Massive bilateral serous retinal detachment in a case of hypertensive chorioretinopathy. *Case Rep Ophthalmol*. 2014;5(2):190-194.
3. Ober RR. Pregnancy-induced hypertension (pre-eclampsia eclampsia). In: Ryan SJ, editor. *Retina*, St Louis: CV Mosby;1994. p . 1393-1403.
4. Besharse J, Bok D. The retina and its disorders. 1st ed. Vol. 9, Breakdown of RPE blood-retinal barrier. Academic Press; 2011. p . 59-67.
5. Younis MT, McKibbin M, Wright A. Bilateral exudative retinal detachment causing blindness in severe pre-eclampsia. *J Obstet Gynaecol*. 2009;27(8):847-848.
6. Lena CW. Vascular permeability- the essentials. *Ups J Med Sci*. 2015;120(3):135-143.
7. Schultz KL, Birnbaum AD, Goldstein DA. Ocular disease in pregnancy. *Curr Opin Ophthalmol*. 2005;16(5): 308-314.
8. Roos NM, Wiegman MJ, Jansonius NM, et al. Visual disturbances in (pre)eclampsia. *Obstet Gynecol Surv*. 2012;67(4):242-250.
9. Riva CE, Titze P, Hero M, et al. Effect of acute decreases of perfusion pressure on choroidal blood flow in humans. *Invest Ophthalmol Vis Sci*. 1997;38(9):1752-1760.
10. Khawla A. The eye and the visual system in preeclampsia /eclampsia: What to expect? *Saudi J Ophthalmol*. 2013;27(1):51-53.
11. Kim EY, Lew HM, Song JH. Effect of intravitreal bevacizumab (Avastin®) therapy in malignant hypertensive retinopathy: A report of two cases. *J Ocul Pharmacol Ther*. 2012;28(3):318-322.
12. McFarland TJ, Rhoads AD, Hartzell M, et al. Bevacizumab levels in breast milk after long-term intravitreal injections. *Retina*. 2015;35(8):1670-1673.
13. Grzybowski A, Told R, Sacu S, Bandello F, et al. Update on intravitreal injections: Euretina expert consensus recommendations. *Ophthalmologica*. 2018;239(4):181-193.