

Successful treatment of scleral perforation in a patient with surgically induced necrotizing scleritis

Kiew Ing **Tiong**¹, Hao Chi **Ho**¹, Rohanah binti **Alias**²

¹*Ophthalmology Department, Sarawak General Hospital, Kuching, Sarawak, Malaysia;*

²*Ophthalmology Department, Hospital Kuala Lumpur, Kuala Lumpur, Malaysia*

Clinical context

A 59-year-old man presented with pain in the left eye and worsening vision for 1 day. He had underlying bilateral, surgically induced necrotizing scleritis following pterygium surgeries on immunosuppressive therapy, steroid-induced glaucoma, and central retinal vein occlusion. His visual acuity declined from hand movement to light perception in the left eye.

Question 1

Describe the findings in Figure 1a.

Question 2

What are the treatments given in Figure 1b?

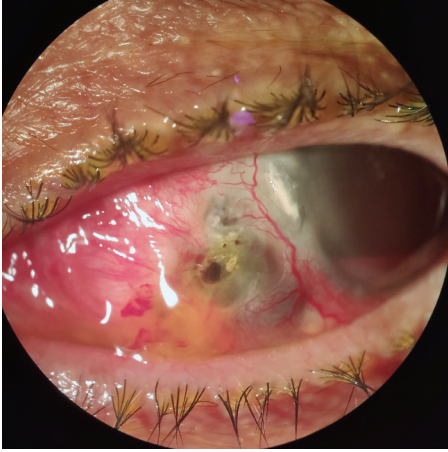


Fig. 1a.

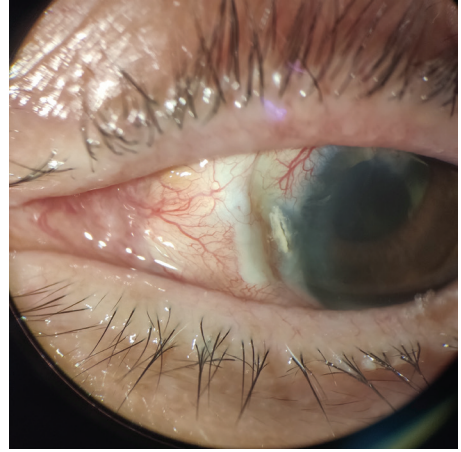


Fig. 1b.

Answer 1

Slit-lamp photograph of the left eye demonstrating three nasal scleral perforations, with the biggest perforation measuring 1 mm horizontally and 1 mm vertically at 8 o'clock and another two pinpoint scleral perforations above it at 9 o'clock. There was presence of vitreous loss and underlying scleral thinning.

Answer 2

Vitrectomy, scleral patch grafting, and amniotic membrane transplantation were performed. Globe integrity was restored and his pain resolved. The patient was treated with intravenous methylprednisolone 250 mg qid for 3 days, followed by oral prednisolone 1 mg/kg and tapered slowly. Immunosuppressive agents, which included azathioprine 50 mg bd and cyclosporine 150 mg od, were given. At the 8-month postoperative follow-up, visual acuity was no worse than preoperative visual acuity, with no recurrence or scleral patch rejection. Scleral grafting in conjunction with systemic immunosuppressive therapy halted the progression of the destructive process.^{1,2}

References

1. Nguyen QD, Foster CS. Scleral patch graft in the management of necrotizing scleritis. *Int Ophthalmol Clin*. 1999;39(1):109-131.
2. Sainz de la Maza M, Tauber J, Foster CS. Scleral grafting for necrotizing scleritis. *Ophthalmology*. 1989;96(3):306-310.