

# Case series of clinical features in siblings with X-linked juvenile retinoschisis

Eng Kah Joon<sup>1</sup>, Malisa Ami<sup>2</sup>, Safinaz Mohd Khialdin<sup>1</sup>

<sup>1</sup>Department of Ophthalmology, Faculty of Medicine, Universiti Kebangsaan Malaysia Medical Centre, Kuala Lumpur, Malaysia; <sup>2</sup>Sunway Damansara Specialist Centre, Selangor, Malaysia

## Abstract

X-linked juvenile retinopathy (XLRS) is a rare inherited bilateral vitreoretinal dystrophy which usually affects males early in life. We describe the clinical findings, outcome, and challenges in treatment of three siblings diagnosed with XLRS. Three siblings with ages ranging from 5 to 9 years old presented with reduced visual acuity (VA) and posterior segment showing varying degrees of vitreous veil and spoke-wheel maculopathy. Optical coherence tomography (OCT) of the macula was performed, revealing retinoschisis in all eyes. All three siblings were diagnosed with XLRS and were started on topical brinzolamide twice daily. OCT was repeated at 6 months and 18 months. At 18 months, three eyes showed stable VA and three eyes showed improved in VA. One out of the three eyes with stable VA showed improved retinoschisis while the other two eyes showed worsening retinoschisis. On the other hand, one out of the three eyes with improved VA had improved retinoschisis and the other two had worsening retinoschisis. We demonstrated that the VA of patients with retinoschisis is not directly proportional to the degree of splitting of the neurosensory retina. Retinoschisis treatment is challenging, as there is no one proven effective treatment up to date.

**Keywords:** macular degeneration, siblings, visual acuity, X-linked juvenile retinoschisis

---

**Correspondence:** Safinaz Mohd Khialdin, Consultant Ophthalmologist, Department of Ophthalmology, Faculty of Medicine, Universiti Kebangsaan Malaysia Medical Centre, Jalan Yaacob Latif, Bandar Tun Razak, 56000 Cheras, Kuala Lumpur, Malaysia.  
E-mail: drsafinaz\_1978@yahoo.com.my

---

## Abstrak

Retinoschisis juvana 'X-linked' ("X-linked juvenile retinoschisis" [XLRS]) adalah sejenis penyakit keturunan distrofi retina yang jarang ditemui dan sering melibatkan jejak pada usia muda. Di sini kami menerangkan manifestasi klinikal dan cabaran dalam rawatan tiga adik beradik yang dikenalpasti mendapat penyakit XLRS. Tiga adik beradik yang usia antara 5 hingga 9 tahun mengadu kurang ketajaman penglihatan. Pemeriksaan mata mendapati berbagai tahap keterukkan 'vitreous veil' dan makulopati jejari roda (spoke-wheel maculopathy). Pengimbasan tomografi koheren optikal ke atas makula mengesahkan diagnosa ini. Ketiga adik beradik kemudiannya dirawat dengan ubat titis mata; Brinzolamide untuk digunakan dua kali sehari. Pengimbasan tomografi koheren optikal diulangi enam and lapan belas bulan kemudian. Dari pemeriksaan klinikal didapati tiga mata dari ketiga-tiga beradik ini mempunyai ketajaman penglihatan yang stabil, manakala tiga mata lagi menunjukkan penambahbaikan dalam ketajaman penglihatan. Daripada tiga mata dengan ketajaman penglihatan yang stabil, satu darinya menunjukkan pengurangan retinoschisis dan dua mata yang lain menunjukkan retinoschisis yang semakin teruk. Sebaliknya, satu dari tiga mata dengan ketajaman penglihatan yang lebih baik telah mengalami pengurangan retinoschisis dan dua yang lain mengalami retinoschisis yang semakin teruk. Berdasarkan pemantauan klinikal, ketajaman penglihatan pesakit retinoschisis adalah tidak selaras dengan tahap kelekangan retina neurosensori. Rawatan retinoschisis adalah mencabar kerana tiada ubat atau kaedah terkini yang terbukti berkesan.

*Kata kunci:* adik beradik, degeneratif makula, ketajaman penglihatan, retinoschisis juvana 'X-linked'

## Introduction

X-linked juvenile retinoschisis (XLRS) is a rare inherited bilateral vitreoretinal dystrophy which usually affects males early in life.<sup>1</sup> It is caused by a mutation of the *RS1* gene, which is responsible for encoding retinoschisin for intercellular adhesion. XLRS causes splitting of the retina. Splitting of the retinal nerve fiber layer and ganglion cell layers was reported in early histopathology studies.<sup>2</sup> However, with the development of spectral-domain optical coherence tomography (SD-OCT), the most common location of schisis cavities was reported to involve the inner nuclear layer, with occasional involvement of the outer plexiform and outer nuclear layers.<sup>3</sup> In this case series, we describe the clinical features as well as ophthalmoscopic and SD-OCT findings of three siblings with XLRS. Table 1 provides a summary of the cases.

Table 1. Summary of the clinical findings at first visit, 6 months, and 18 months

	Case 1		Case 2		Case 3	
<b>Age (years)</b>	5		9		7	
<b>Laterality</b>	RE	LE	RE	LE	RE	LE
<b>Refraction</b>	+2.50 DS	+3.25 DS	+2.75 DS	+3.25 DS	+3.50 DS	+4.50 DS
<b>BCVA (First visit)</b>	6/60	6/18	6/18	6/18	6/18	6/18
<b>OCT (First visit)</b>	362 $\mu\text{m}$	363 $\mu\text{m}$	535 $\mu\text{m}$	510 $\mu\text{m}$	501 $\mu\text{m}$	404 $\mu\text{m}$
<b>BCVA (6 months)</b>	6/120	6/18	6/18	6/18	6/24	6/36
<b>OCT (6 months)</b>	347 $\mu\text{m}$	374 $\mu\text{m}$	550 $\mu\text{m}$	549 $\mu\text{m}$	476 $\mu\text{m}$	436 $\mu\text{m}$
<b>BCVA (18 months)</b>	6/24	6/18	6/12	6/12	6/18	6/18
<b>OCT (18 months)</b>	347 $\mu\text{m}$	379 $\mu\text{m}$	566 $\mu\text{m}$	577 $\mu\text{m}$	475 $\mu\text{m}$	439 $\mu\text{m}$

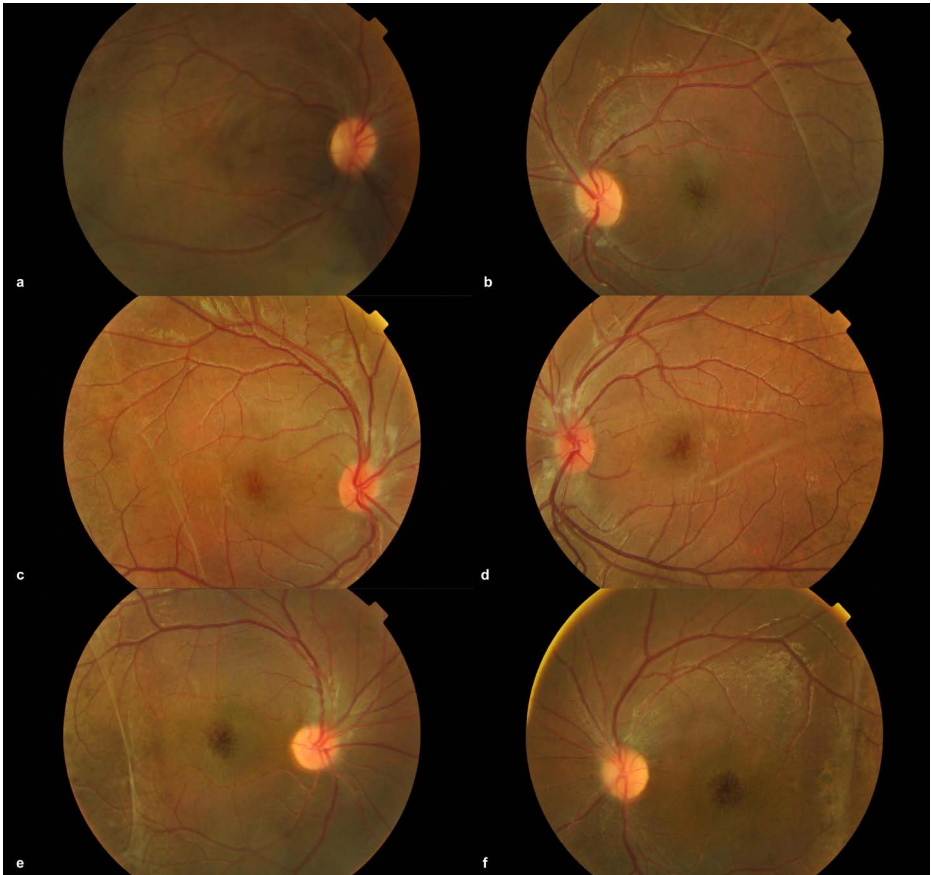
BCVA: best-corrected visual acuity; RE: right eye; LE: left eye; DS: dioptres; OCT: optical coherence tomography

## Case presentation

### Case 1

The first case concerns a 5-year-old full-term boy. The boy was initially referred for right eye strabismus at the age of 3 years. On examination, visual acuity (VA) in both eyes was 6/9.5 with Cardiff acuity test at 1 meter. Cycloplegic refraction showed hypermetropia of +2.75 diopters (DS) in both eyes. Cover test revealed alternating exotropia with left eye fixation, normal anterior segments, and no fundus abnormality. In view of good vision, no glasses were prescribed. The patient was given a 6-month appointment, but the boy defaulted to follow-up.

The boy was referred again by the Child Development Clinic 2 years after the first visit for poor vision in the right eye at 5 years of age. The mother denied worsening of the squint and she did not realize that her child was experiencing blurred vision. On examination, cycloplegic refraction revealed +2.50 DS in the right eye and +3.25 DS in the left eye. Best-corrected visual acuity (BCVA) was 6/60 in the right eye and 6/18 in the left eye. Cover test showed similar findings of alternating exotropia with left eye fixation. Bilateral anterior segment examinations were unremarkable. Bilateral fundus examination (Fig. 1a-b) revealed spoke-like striae radiating from the foveola



*Fig. 1.* Colour fundus photographs of the right and left eyes showing bilateral spoke-wheel appearance radiating from the foveola with blunted foveal reflex and vitreous veils. (a, b) Case 1; (c, d) Case 2; (e, f) Case 3.

with blunted foveal reflex, vitreous veils, and pigmentary changes of the retina. Bilateral macular SD-OCT (Fig. 2a-b) showed cystic spaces in the inner nuclear and outer nuclear layers, with loss of the foveal contour. Central subfield foveal thickness (CSFT) was 362  $\mu\text{m}$  in the right eye and 363  $\mu\text{m}$  in the left eye. He was diagnosed with alternating exotropia with left eye fixation, bilateral eye hypermetropia with right eye amblyopia, and bilateral eye XLRs. He was prescribed glasses and was started on left eye patching 2 hours per day as well as topical brinzolamide twice daily. In view of XLRs being an inherited disease, his two brothers (Case 2 and Case 3) and parents were asked to come for an eye screening. Both parents were screened with macular SD-OCT and their results showed normal retinal configuration with no signs suggestive of XLRs.

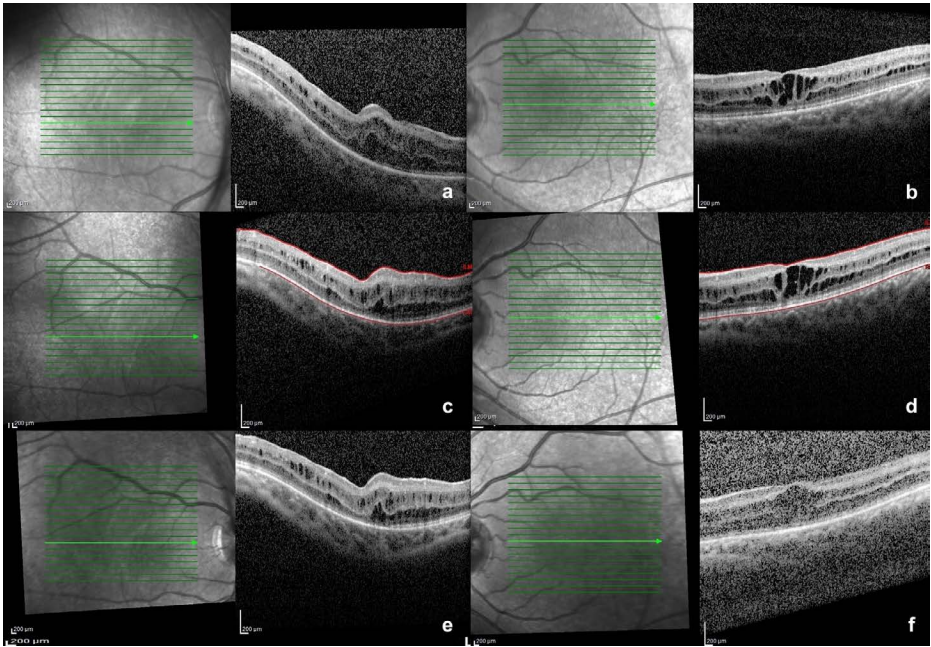


Fig. 2. Case 1: Optical coherence tomography images of the right and left eyes showing schisis cavities in the fovea of both eyes. (a, b) First visit; (c, d) at 6 months; (e, f) at 18 months.

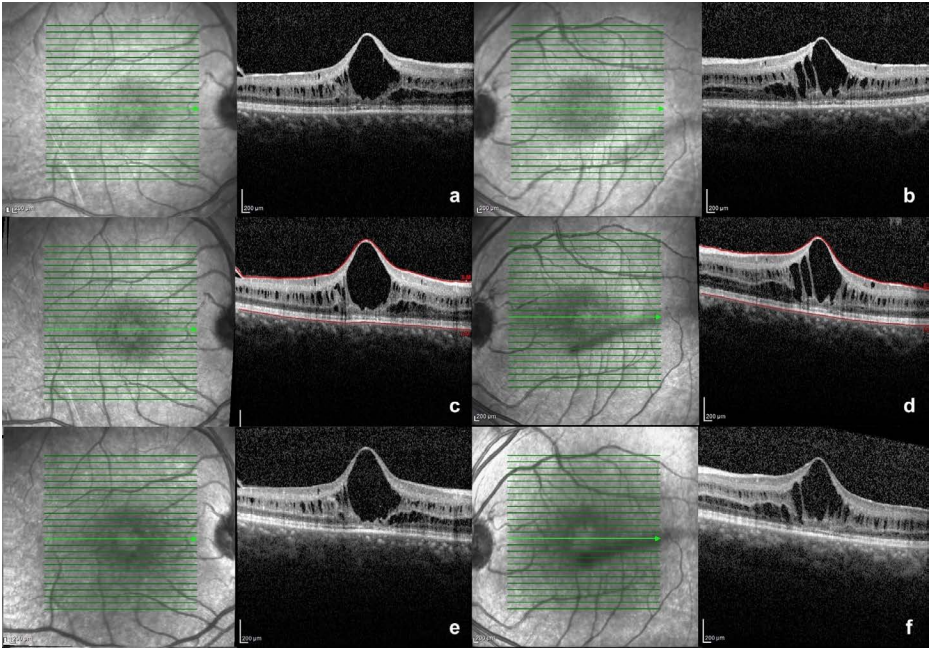
Six months later, BCVA was 6/120 in the right eye and 6/18 in the left eye. Macular SD-OCT (Fig. 2c-d) showed CSFT in the right eye had improved from 362  $\mu\text{m}$  to 347  $\mu\text{m}$ , while the left eye had slightly worsened from 363  $\mu\text{m}$  to 374  $\mu\text{m}$ . Topical brinzolamide twice daily together with glasses and patching were continued. At 18 months, BCVA in the right eye improved to 6/24 while the left eye remained at 6/18. Macular SD-OCT (Fig. 2e-f) showed stable retinoschisis. CSFT was 347  $\mu\text{m}$  in the right eye and 379  $\mu\text{m}$  in the left eye. Hence, topical brinzolamide twice daily and patching were continued.

## Case 2

A 9-year-old boy, the eldest of the three siblings, was brought for XLRS screening. He had been diagnosed with hyperopia by a private optometrist 2 years prior and had been prescribed spectacles. Further history revealed that he had complained of blurred vision for the past 2 years, even after refractive correction.

On examination, BCVA in both eyes was 6/18. Refraction showed +2.75 DS in the right eye and +3.25 DS in the left eye. Anterior segment examinations were unremarkable. Both fundi (Fig. 1c-d) showed spoke-wheel appearance of the macula with vitreous veils in the posterior pole. Bilateral macular SD-OCT (Fig. 3a-b) revealed cystoid spaces involving the inner nuclear and outer nuclear layers, with





*Fig. 3.* Case 2: Optical coherence tomography images of the right and left eyes showing marked schisis cavities in the fovea of both eyes, with large bilateral foveal cysts. (a, b) First visit; (c, d) at 6 months; (e, f) at 18 months.

loss of foveal contour. CSFT was 535  $\mu\text{m}$  in the right eye and 510  $\mu\text{m}$  in the left eye. XLRS was diagnosed and he was started on topical brinzolamide twice daily.

Six months later, BCVA remained the same. Macular SD-OCT (Fig. 3c-d) showed worsening of bilateral eye retinoschisis with CSFT of 550  $\mu\text{m}$  in the right eye and 549  $\mu\text{m}$  in the left eye. At 18 months, bilateral BCVA improved to 6/12. Bilateral SD-OCT (Fig. 3-f) showed progression despite treatment. CSFT in the right eye increased to 566  $\mu\text{m}$  and to 577  $\mu\text{m}$  in the left eye. Topical brinzolamide was increased to three times daily.

### Case 3

The third case was a 7-year-old boy, the sibling of the two boys mentioned above. He was also screened for XLRS. The child denied blurred vision or any other eye symptoms. On examination, cycloplegic refraction revealed +3.50 DS in the right eye and +4.50 DS in the left eye, with bilateral BCVA of 6/18. Ocular anterior segment examinations were normal. Similar to his brothers, his fundus examination (Fig. 1e-f) showed spoke-wheel appearance of the macula and vitreous veil involving the posterior pole in both eyes. There was also splitting of the retinal neurosensory layers by the cystoid spaces involving the fovea, as shown in the macular SD-OCT

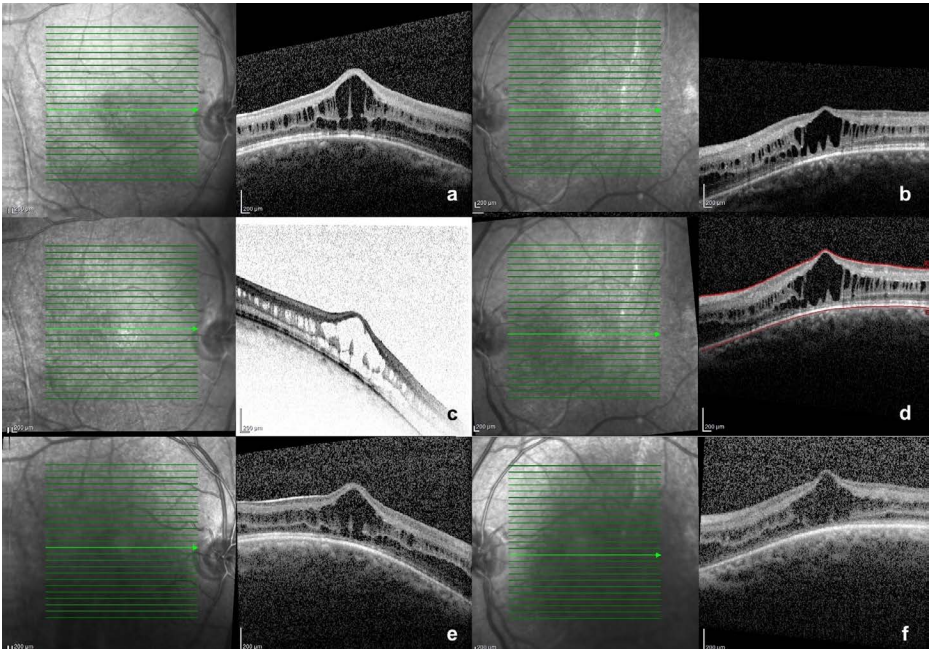


Fig. 4. Case 3: Optical coherence tomography images of the right and left eyes showing marked schisis cavities in the fovea of both eyes, with large bilateral foveal cysts. (a, b) First visit; (c, d) at 6 months; (e, f) at 18 months.

(Fig. 4a-b). CSFT was 501  $\mu\text{m}$  in the right eye and 404  $\mu\text{m}$  in the left eye. He was diagnosed with XLRS. Spectacle correction was prescribed and topical brinzolamide twice daily was started.

Six months later, the BCVA dropped to 6/24 in the right eye and 6/36 in the left eye. Macular SD-OCT (Fig. 4c-d) showed improvement of the retinoschisis in the right eye with CSFT reduced to 476  $\mu\text{m}$ , but worsening of the retinoschisis in the left eye with CSFT of 436  $\mu\text{m}$ . Topical brinzolamide was continued. At 18 months, bilateral BCVA was 6/18. No progression was seen on bilateral macular SD-OCT (Fig. 4e-f), with a CSFT of 475  $\mu\text{m}$  in the right eye and 439  $\mu\text{m}$  in the left eye. Topical brinzolamide twice daily was continued.

## Discussion

XLRS is the most common macular degenerative disease in boys and young men.<sup>4</sup> Females are usually asymptomatic carriers with incidental findings of minor retinal abnormalities during routine examination.<sup>5</sup> The pathogenesis of XLRS is due to a mutation of the *RS1* gene, which is responsible for encoding of retinoschisin.

Failure of retinoschisin formation will lead to failure of cell-cell adhesion, which can be seen clinically as splitting of the inner retinal layers.<sup>6</sup>

XLRS usually expresses symmetrically in both eyes; however, patients can present with a marked asymmetry of visual function.<sup>7</sup> Onset can be quite varied. It has been reported in infants as young as 3 months old. Patients may present with VA ranging from 6/6 to blindness. Several studies have shown that reduction of VA usually occurs before puberty; subsequent VA may remain unchanged for many years in most cases.<sup>1,8</sup> In our first case, although both eyes expressed a similar degree of retinoschisis changes, VA in the right eye was far worse than the left eye. This could be due to the patient having right eye amblyopia secondary to alternating exotropia with left eye fixation. Thus, a trial of left eye patching 2 hours a day was started. After 18 months of patching, although there was no marked reduction of retinoschisis, BCVA in the right eye improved from 6/60 to 6/24. This explained the possibility of right eye amblyopia that improved with patching.

Hyperopia is commonly seen in patients with XLRS. Our patients had refractive errors ranging from +2.50 DS to +4.50 DS, which corresponds to a mean refractive error of approximately +2.5 DS found in most studies.<sup>8</sup>

XLRS is diagnosed with SD-OCT, which is fast, easy, and painless, and thus useful in children. Our youngest patient, who was only 5 years old, was cooperative enough for an SD-OCT examination, which can differentiate retinoschisis from retinal detachment. One study reported that foveal retinoschisis can be seen in 70% of XLRS patients, while peripheral retinoschisis is seen in 60% of XLRS patients.<sup>9</sup> Our three patients showed clinically characteristic foveal retinoschisis demonstrable on SD-OCT. Splitting of the retinal nerve fibre layer and ganglion cell layers was reported in early histopathology studies.<sup>2</sup> However, in recent studies, foveal schisis in the inner nuclear and outer plexiform layers are commonly present.<sup>10,11</sup> In our study, macular SD-OCT showed a similar pattern in all three cases, with the retinal split involving the inner and outer retina. Coalescing of these cystoid spaces in the fovea could cause further loss of VA in the future.

There is no definite treatment for XLRS currently. However, multiple studies have suggested that carbonic anhydrase inhibitors (CAIs) play an important role in reducing cystoid macular oedema in XLRS. CAIs increase fluid transport across the retinal pigment epithelium layer due to its inhibition of carbonic anhydrase present in the retinal pigment epithelium, thus reducing the cystoid spaces in the neurosensory retina and enhancing retinal adhesiveness.<sup>12</sup> Some studies have reported that 47% to 70% of XLRS patients showed reduced central retinal thickness after starting on CAIs.<sup>13,14</sup> A recent study by Verbakel *et. al* showed that response to CAIs (oral acetazolamide with or without topical CAIs) could be observed as early as 1 month after starting of treatment. Previous studies have also shown different responses to CAIs; improvement in BCVA was not always consistent with a reduction in the size of the macular cyst.<sup>15</sup> This might explain



why the changes in our patients' VA were not consistent with the improvement or worsening of the retinoschisis demonstrated on SD-OCT.

In this case series, three eyes showed stable VA and three eyes showed improved VA after starting topical brinzolamide twice daily. Out of the three eyes with stable VA, one eye showed improved retinoschisis while the other two eyes showed worsening retinoschisis. On the other hand, one out of the three eyes with improved VA had improved retinoschisis and the other two had worsening retinoschisis on SD-OCT. We could see that only two out of the six eyes had VA improvement and reduction in foveal thickness. Treatment with CAIs in our cases was not as promising as in other studies. We faced a few challenges in treating the three brothers, compliance being the main issue. The children were given topical brinzolamide twice daily initially because they needed to attend school. The mother admitted to forgetting to instil the topical brinzolamide occasionally. Furthermore, due to the COVID-19 pandemic, there were missed appointments and discontinuation of eye drops for a short period of time for all three brothers. Although the amount of eye drops instilled was the same for the three brothers, only Case 2 showed progression in CSFT at 18 months.

## **Conclusion**

XLRS is a rare inherited bilateral vitreoretinal dystrophy with no definite treatment currently. We found no direct correlation between macular thickness and BCVA in our case series. However, CAIs remain a treatment option, as some cases of XLRS may respond to CAI treatment.

## **Declarations**

### **Ethics approval and consent to participate**

Not required.

### **Consent for publication**

### **Competing interests**

None to declare.

### **Funding**

None to declare.

### **Acknowledgements**

None to declare.

## References

1. Ewing CC, Ives EJ. Juvenile hereditary retinoschisis. *Trans Ophthalmol Soc UK* 1969;89(1):29-39.
2. Yanoff M, Rahn EK, Zimmerman LE. Histopathology of juvenile retinoschisis. *Arch Ophthalmol*. 1968;79(1):49-53.
3. Jia Y, Pearse AK, Chunhui J, Wenji W, Gezhi X. Foveomacular Schisis in Juvenile X-Linked Retinoschisis: An Optical Coherence Tomography Study. *Am J Ophthalmol*. 2010;149(6):973-978.
4. Forsius H, Krause U, Helve J, et al. Visual acuity in 183 cases of X-chromosomal retinoschisis. *Can J Ophthalmol*. 1973;8(3):385-393.
5. Kim LS, Seiple W, Fishman GA, Szlyk JP. Multifocal ERG findings in carriers of X-linked retinoschisis. *Doc. Ophthalmol*. 2007;114(1):21-26.
6. Robert SM, Ulrich K, Bernhard HFW. X-linked juvenile retinoschisis: Clinical diagnosis, genetic analysis, and molecular mechanisms. *Prog Retin Eye Res*. 2012;31(3):195-212.
7. Tantri A, Vrabec TR, Cu-Unjieng A, Frost A, Annesley Jr WH, Donoso LA. X-linked retinoschisis: a clinical and molecular genetic review. *Surv Ophthalmol*. 2004;49(2):214-230.
8. Lisch W. Hereditary vitreoretinal degenerations. *Dev Ophthalmol*. 1983;8(1):19-32.
9. George ND, Yates JR, Moore AT. X-linked retinoschisis. *Br J Ophthalmol*. 1995;79(7):697-702.
10. Ozdemir H, Karacorlu S, Karacorlu M. Optical coherence tomography findings in familial foveal retinoschisis. *Am J Ophthalmol*. 2004;137(1):179-81.
11. Apushkin MA, Fishman GA, Janowicz MJ. Correlation of optical coherence tomography findings with visual acuity and macular lesions in patients with X-linked retinoschisis. *Ophthalmology*. 2005;112(3):495-501.
12. Salvatore S, Fishman GA, Genead MA. Treatment of cystic macular lesions in hereditary retinal dystrophies. *Surv Ophthalmol*. 2013;58(6):560-584.
13. Verbakel SK, Ven DVJ, LeBlanc LM, et al. Carbonic Anhydrase Inhibitors for the Treatment of Cystic Macular Lesions in Children With X-Linked Juvenile Retinoschisis. *Invest Ophthalmol Vis Sci*. 2016;57(13):5143-5147.
14. Testa F, Dilorio V, Gallo B, et al. Carbonic anhydrase inhibitors in patients with X-linked retinoschisis: effects on macular morphology and function. *Ophthalmic Genet*. 2019;40(3):207-212.
15. Gurbaxani A, Wei M, Succar T, et al. Acetazolamide in retinoschisis: a prospective study. *Ophthalmology*. 2014; 121(3):802-803.