

# Remarkable ophthalmic improvement following early diagnosis and treatment of paediatric prolactinoma-compressing optic chiasm: a case report

Indra Tri **Mahayana**<sup>1</sup>, Muhamad Dwi **Nugroho**<sup>1</sup>, Sahara **Effendi**<sup>2</sup>, Natalia Christina **Angsana**<sup>1</sup>, Madarina **Julia**<sup>2</sup>

<sup>1</sup>Department of Ophthalmology, Faculty of Medicine, Public Health, and Nursing, Universitas Gadjah Mada, Yogyakarta, Indonesia; <sup>2</sup>Department of Paediatrics, Faculty of Medicine, Public Health, and Nursing, Universitas Gadjah Mada, Yogyakarta, Indonesia

## Abstract

*Background:* Prolactinomas frequently manifest as visual field defects and are often undetected due to their slow gradual progression. Chronic optic nerve compression will result in irreversible diffuse nerve atrophy and is associated with permanent severe vision and field loss.

*Case report:* A 12-year-old boy presented with acute visual loss, right eye ptosis, and decreased visual acuity (VA). Band atrophy at the optic disc and bitemporal hemianopia were found. MRI revealed a homogenic solid lesion in the intrasellar to suprasellar region, suggesting pituitary macroadenoma. Laboratory results showed increased prolactin hormone (33.6 ng/ml), decreased thyroid hormones (FT4 0.68 mg/dL and TSH 0.07 mg/dL), and decreased testosterone (<0.025 ng/mL). Subfrontal craniotomy, hormonal therapy, and photon radiotherapy were done. On follow-up, VA was 6/6 and band atrophy and bitemporal hemianopia had disappeared.

---

**Correspondence:** Indra Tri Mahayana, MD, PhD, Department of Ophthalmology, Faculty of Medicine Public Health and Nursing, Universitas Gadjah Mada, Jl, Farmako, Sekip Utara, Yogyakarta, Indonesia.

E-mail: [indra.tri.m@mail.ugm.ac.id](mailto:indra.tri.m@mail.ugm.ac.id)

---

*Conclusion:* Early diagnosis and treatment of prolactinomas might give a good clinical outcome for the patient.

*Keywords:* craniotomy, pituitary macroadenoma, neuro-ophthalmology, prolactinoma, visual field loss

## **Diagnosa dan rawatan awal untuk prolaktinoma yang melibatkan chiasm optik telah memberi pemulihan oftalmik yang ketara dalam pesakit kanak-kanak: laporan kes**

### **Abstrak**

*Pengenalan:* Prolaktinoma kerap menjelma sebagai kecacatan medan penglihatan dan selalunya tidak dapat dikesan kerana perkembangannya yang perlahan. Mampatan saraf optik kronik akan mengakibatkan atrofi saraf optik yang kekal dan dikaitkan dengan penglihatan teruk yang kekal serta.

*Ilustrasi kes:* Ini ialah laporan kes seorang budak lelaki berumur 12 tahun dengan kehilangan penglihatan akut, ptosis mata kanan, penurunan ketajaman penglihatan (VA). Atrofi jalur pada saraf optik dan kehilangan medan penglihatan bitemporal ditemui. MRI menunjukkan satu ketumbuhan sekata yang pejal dari kawasan intrasellar ke suprasellar konsisten dengan makroadenoma pituitari. Pemeriksaan makmal menunjukkan peningkatan hormon prolaktin (33.6 ng/ml) dan penurunan kedua-dua hormon tiroid (FT4 0.68 mg/dL dan TSH 0.07 mg/dL) dan testosteron (< 0.025 ng/mL). Kraniotomi subfrontal, terapi hormon, dan radioterapi photon telah dilakukan. Pada susulan di September 2020, VA ialah 6/6 dan atrofi jalur serta hemianopia bitemporal telah hilang.

*Kesimpulan:* Diagnosis awal dan rawatan prolaktinoma mungkin memberikan hasil klinikal yang baik untuk pesakit.

*Kata kunci:* kehilangan medan penglihatan, kraniotomi, makroadenoma pituitari, neuro-oftalmologi, prolaktinoma

### **Introduction**

Prolactinomas are benign tumours of the pituitary gland that are grouped into pituitary adenomas. There are two main types of tumours that occupy the

pituitary fossa: craniopharyngiomas and pituitary adenomas. Craniopharyngiomas account for up to 90% of paediatric tumours arising in the pituitary region and are the most common paediatric neoplasm associated with hypopituitarism in children. Pituitary adenomas, on the other hand, comprise only 2.7% of supratentorial tumours in children, are usually benign, and are classified according to size, functional status, primary cell origin, and secreted hormone. Prolactinomas are the most common pituitary adenomas in adults and children, with 53% of paediatric pituitary adenomas identified as prolactinomas.<sup>1</sup> Presenting symptoms of prolactinoma include galactorrhoea, headache, visual field defects, menstrual disorders, amenorrhoea, blurred vision, and growth retardation.<sup>2</sup> Therefore, male paediatric patients with growth retardation should undergo ophthalmic examinations such as visual acuity (VA) and visual field tests.

## Case presentation

A 12-year-old boy was referred to our hospital for acute visual loss. Two weeks before hospitalization he suffered orbital discomfort and visual loss associated with frontal headache. The headache had been felt for 6 months. On admission in June 2020, ophthalmological examination revealed ptosis in the right eye (severe ptosis

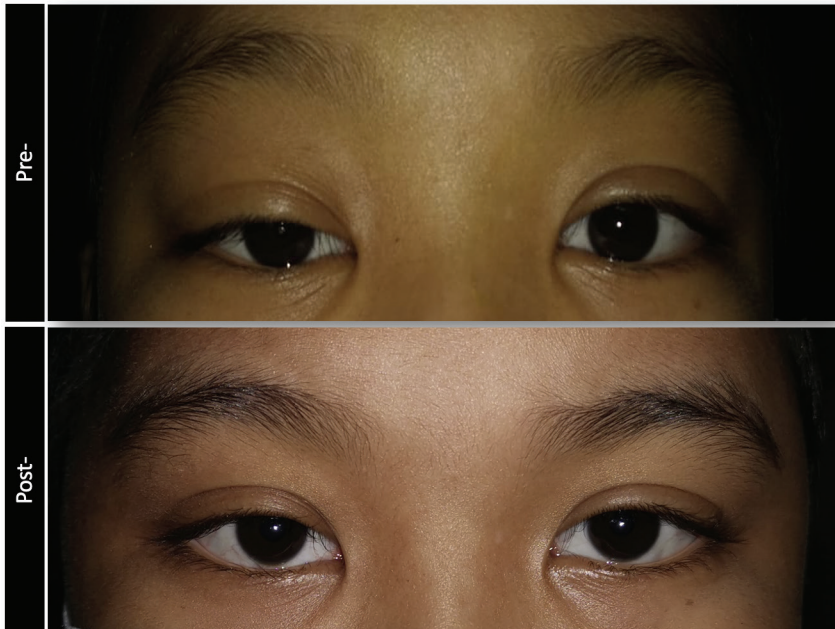

Fig. 1. (Top) Preoperatively, the patient had ptosis in the right eye (note the use of the frontal muscle). (Bottom) Improvement after treatment protocols.

with marginal reflex distance 1 = 0 mm, levator function test = 2 mm, (Fig. 1 top), decreased bilateral pupillary reflex with VA 6/15 in both eyes, decreased contrast sensitivity, and dyschromatopsia. Nine gaze eye movement examination showed a right oculomotor nerve palsy (Fig. 2). The patient was suspected with growth retardation as his height was 135 cm (below the 5th percentile). Band atrophy was found at the optic discs (Fig. 3). Contrast-enhanced magnetic resonance imaging of the brain showed a homogenic solid lesion located in the intrasellar to suprasellar region, lobulated in shape with size 5.2 cm x 2.4 cm x 3.3 cm, which the radiologist assessed as pituitary macroadenoma (Fig. 4). Bitemporal hemianopia appeared on the Humphrey Field Analyzer (Carl Zeiss Meditec AG, Jena, Germany) (Fig. 5). Laboratory examination showed increased prolactin hormone (33.6 [0.9–12.9] ng/ml), decreased thyroid hormones (FT4 0.68 [0.98–1.63] mg/dL and TSH 0.07 [0.51–4.30] mg/dL), and decreased testosterone (< 0.025 [0.03–0.68] ng/mL).

The patient underwent a treatment protocol consisting of bromocriptine tab 2.5 mg b.i.d, levothyroxine tab 0.025 mg once daily, hydrocortisone tab 20 mg t.i.d, and desmopressin tab 0.05 mg b.i.d for 1 month. The patient underwent subfrontal craniotomy tumour removal to remove the lesion due to undergoing compressive optic neuropathy by tumour mass. The result was pituitary macroadenoma prolactinoma suspect, with negative immunohistochemical findings of oestrogen receptor, epithelial membrane antigen, and glial fibrillary acidic protein. Tele radiotherapy with 3D photons (conformal photon radiotherapy/3DCRT) was done to clear the residual tumour. Upon follow-up in September 2020, VA had improved to OU 6/6, contrast sensitivity improved to 1.35, ptosis improved to mild ptosis (marginal reflex distance 1 = 2 mm, symmetric between right and left eye, see Fig. 1 bottom), and bitemporal hemianopia had disappeared.

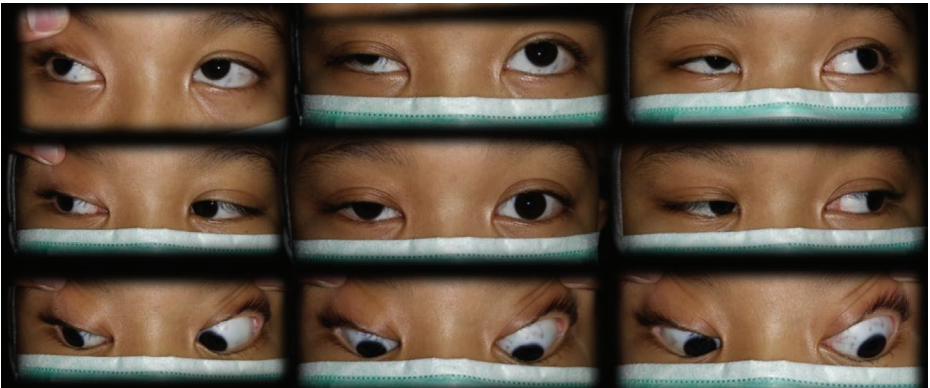

Fig. 2. Nine gaze eye movement examination showed a right oculomotor nerve palsy in the right eye.

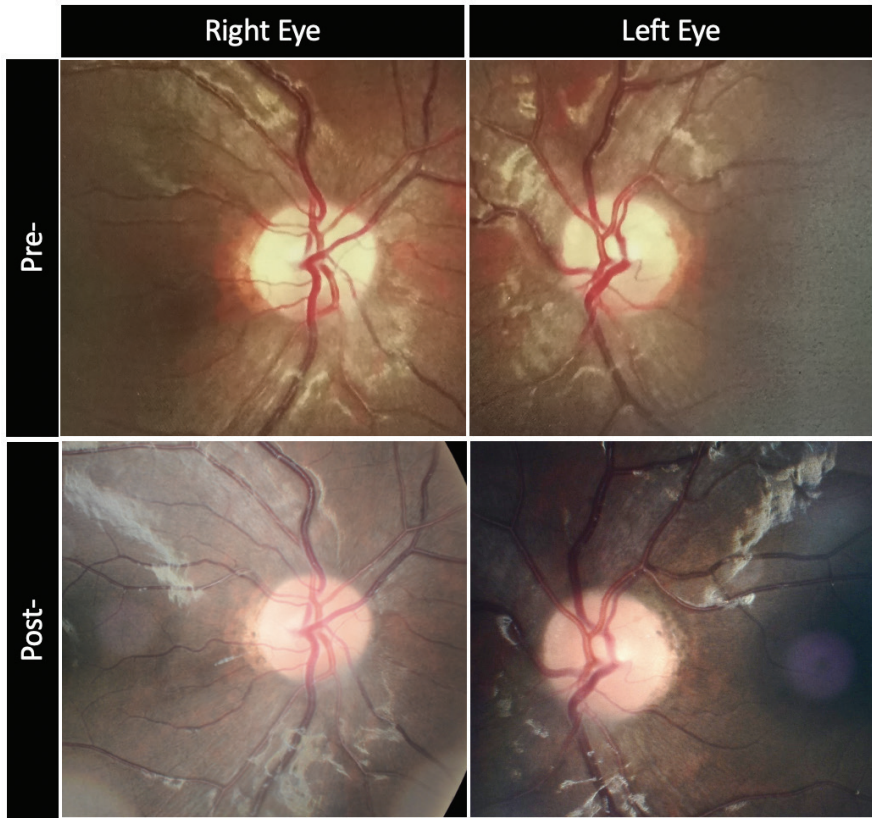


Fig. 3. (Top) Before treatment, the patient had band atrophy due to chiasmal compression. (Bottom) Improvement after treatment protocol (note: no colour reproduction was made).

## Discussion

We report a case of prolactinoma in a 12-year-old boy with compressing optic chiasm resulting in decreased VA, ptosis, and bitemporal hemianopia. In the present study, hyperprolactinemia is under control using hormonal therapy only. Furthermore, compressive optic neuropathy symptoms were improved significantly after surgery and radiotherapy. Chronic nerve compression by a pituitary mass results in diffuse, irreversible atrophy of the optic nerve which is typically associated with permanent severe vision and field loss.<sup>1</sup> If it is not immediately diagnosed, macroprolactinomas have a tendency to grow over time, thus requiring more aggressive treatment.

Treatment goals in this patient included the early release of chiasm compression surgically and hormonally to attain normal gonadal function as well as to ensure

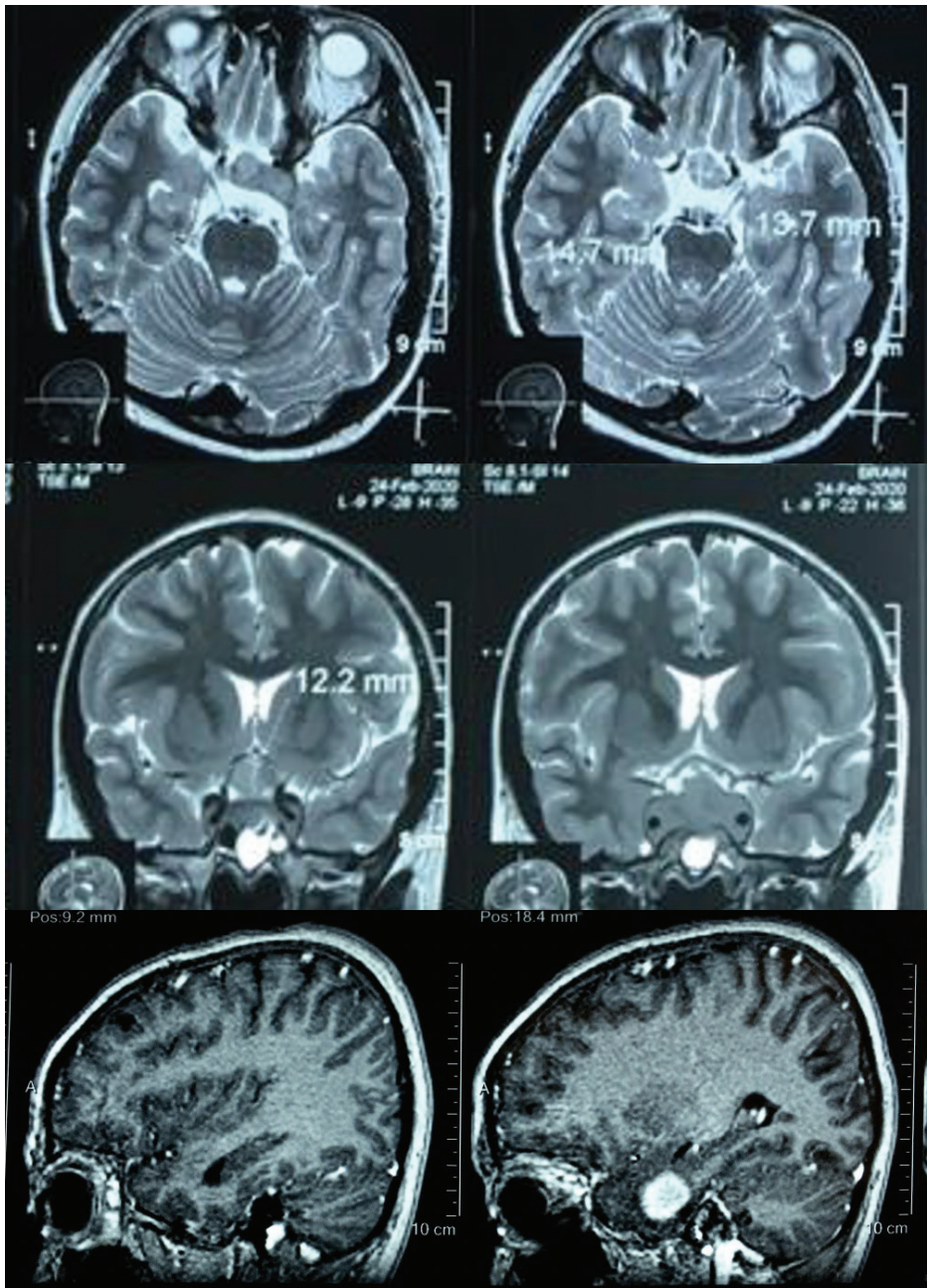


Fig. 4. Magnetic resonance imaging showing a tumour mass in the sellar region compressing the optic chiasm.

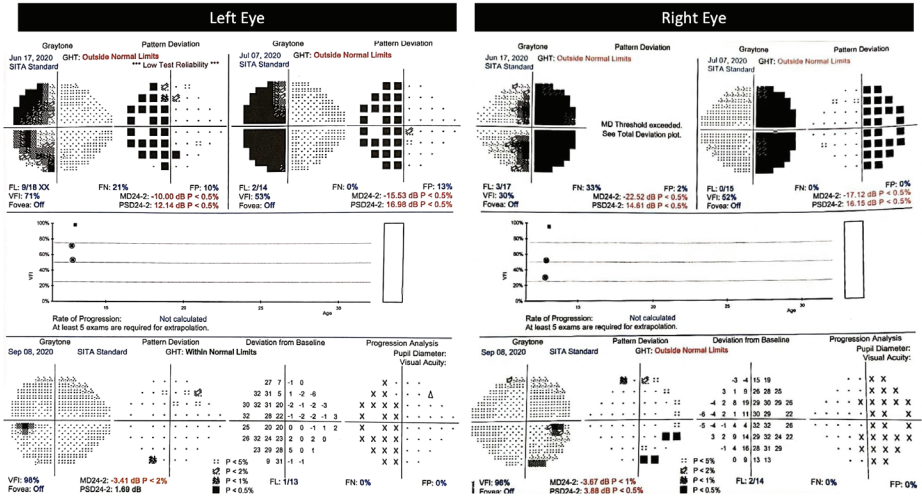


Fig. 5. Improvement of visual field defect after treatment protocols with no sign of bitemporal hemianopia.

future fertility. A systematic review and meta-analysis study showed that disease remission after surgery without dopamine agonist treatment was lower than dopamine agonist treatment alone.<sup>3</sup> Therefore, in this patient, dopamine agonist treatment was administered prior to and after surgery. Dopaminergic agonists are the initial therapy of choice in children, adolescents, and adults due to their effectiveness and tolerance.<sup>4,5</sup> In macroprolactinoma, surgery should be reserved for medically intractable tumours or neurosurgical emergencies.<sup>6</sup> Irradiation might have side effects such as neurological sequelae, hypopituitarism, and increased risk for second malignancies.<sup>7</sup> In this patient, radiation therapy was administered to prevent tumour growth and resolve tumour hypersecretion.<sup>8</sup> After 3 months, prolactin levels and ophthalmic findings were normal.

### Conclusion

Early diagnosis and treatment of prolactinomas might give a good prognosis for the patient. The aim of surgical therapy was to reduce the tumour mass and acquire tissue samples to establish the correct diagnosis. Hormonal therapy can control the disease effectively, with the hopes of restoring prolactin levels to normal and achieving gonadotrophic restoration. Radiotherapy was important to reduce the tumour mass since surgical therapy did not remove the tumour tissue completely.

## Declarations

### Consent for publication

Written informed consent for publication of their clinical details and/or clinical images was obtained from the patient's parent.

### Competing interests

None to declare.

### Funding

None to declare.

### Acknowledgements

None to declare.

## References

1. Kamboj A, Lause M, Kumar P. Ophthalmic manifestations of endocrine disorders-endocrinology and the eye. *Transl Pediatr.* 2017;6(4):286–299.
2. Liu Y, Yao Y, Xing B, et al. Prolactinomas in children under 14. Clinical presentation and long-term follow-up. *Childs Nerv Syst.* 2015 Jun;31(6):909–16.
3. Zamanipoor Najafabadi AH, Zandbergen IM, de Vries F, et al. Surgery as a Viable Alternative First-Line Treatment for Prolactinoma Patients. A Systematic Review and Meta-Analysis. *J Clin Endocrinol Metab.* 2020;105(3):e32–41.
4. Fideleff HL, Boquete HR, Suárez MG, Azaretsky M. Prolactinoma in Children and Adolescents. *Horm Res.* 2009;72(4):197–205.
5. Breil T, Lorz C, Choukair D, et al. Clinical Features and Response to Treatment of Prolactinomas in Children and Adolescents: A Retrospective Single-Centre Analysis and Review of the Literature. *Horm Res Paediatr.* 2018;89(3):157–165.
6. Barker FG 2nd, Klibanski A, Swearingen B. Transsphenoidal surgery for pituitary tumors in the United States, 1996–2000: mortality, morbidity, and the effects of hospital and surgeon volume. *J Clin Endocrinol Metab.* 2003;88(10):4709–19.
7. Brada M, Ajithkumar TV, Minniti G. Radiosurgery for pituitary adenomas. *Clin Endocrinol.* 2004;61(5):531–43.
8. Royce TJ, Loeffler JS, Shih HA. Transsphenoidal Surgery: Complication Avoidance and Management Techniques. USA: Springer, Cham; 2017. Radiation therapy for pituitary tumors. P. 559–579.