

Treatment of conjunctival squamous cell carcinoma: balancing disease eradication with minimising treatment-induced morbidity

Cameron A. **McLintock**^{1,2}, James **McKelvie**^{1,3}, Samer **Hamada**¹

¹Corneoplastic Unit and Eye Bank, Queen Victoria Hospital, NHS Trust, East Grinstead, West Sussex, United Kingdom; ²Department of Ophthalmology, Princess Alexandra Hospital, Brisbane, Queensland, Australia; ³Department of Ophthalmology, Faculty of Medical and Health Sciences, University of Auckland, New Zealand

Abstract

A 41-year-old male presented with a large non-pigmented lesion on the ocular surface involving 8 clock hours of limbus, bulbar conjunctiva, and palpebral conjunctiva. Incisional biopsy confirmed poorly differentiated conjunctival squamous cell carcinoma (SCC). It was staged as a T3, N0, M0 lesion. Treatment was with surgical excision, amniotic membrane transplant, and buccal mucosa graft. Three weekly cycles of 0.04% mitomycin C were administered postoperatively. Six months following excision, although there was no evidence of residual conjunctival SCC, the patient suffered from poor vision, significant pain, and diplopia due to severe dry eye, limbal stem cell deficiency, and symblepharon.

This case illustrates the difficult clinical decisions which confront the clinician when treating conjunctival SCC, particularly with balancing the need to eradicate the disease to prevent local invasion and metastatic spread on the one hand and minimising ocular morbidity on the other.

Keywords: conjunctival intraepithelial neoplasia, conjunctival squamous cell carcinoma

Correspondence: Cameron McIntock: Department of Ophthalmology, Princess Alexandra Hospital, Brisbane, Queensland, Australia.
E-mail: cameron.mcintock@health.qld.gov.au

Rawatan bagi karsinoma sel skuamos pada konjunktiva: mengimbangi antara eradikasi penyakit dan mengurangi morbiditi akibat kesan rawatan

Seorang lelaki berusia 41 tahun dengan satu ketumbuhan tanpa pigmentasi yang besar pada permukaan okular yang melibatkan bahagian limbus pada kedudukan pukul 8, bulbar dan palberal konjunktiva. Biopsi insisional mengesahkan diagnosa karsinoma sel skuamos (SCC) jenis yang kurang perbezaan. Pemeriksaan lanjut mengesahkan peringkat karsinoma sebagai T3, N0 dan M0. Pembedahan eksisi beserta transplantasi membran amniotic dan graf mukosa mulut bukal telah dibuat. Dituruti oleh tiga kali kitaran rawatan dengan mitomycin C 0.04% pada setiap tiga minggu selepas pembedahan.

Pembedahan tersebut berhasil tanpa sebarang residual SCC enam bulan selepas pembedahan. Namun pesakit mengalami masalah penglihatan yang berkurangan, kesakitan yang signifikan dan diplopia disebabkan oleh kekeringan mata yang teruk, defisiensi sel stem limbal dan pembentukan simbleparon.

Kes ini mengilustrasikan kesukaran membuat keputusan klinikal yang dihadapi oleh doktor perawat, terutama dari segi mengimbangi keperluan eradikasi penyakit dan menghalang rebakan setempat dan metastasis pada satu aspek dengan mengurangkan morbiditi okular dari aspek yang lain.

Kata kunci: karsinoma sel skuamosa konjunktiva, neoplasia intraepithelial konjunktiva

Case report

A 41-year-old male was referred with a large lesion on the right globe that had been slowly growing for the previous 10 years. There was no significant past medical history and specifically no history of prior malignancy or immunosuppression. There was no past ophthalmic history.

Examination revealed a corrected distance visual acuity (CDVA) of 20/50 in the right eye and 20/20 in the left eye. There was a non-pigmented, gelatinous lesion involving 8 clock hours of the limbus, the entire temporal and inferior bulbar conjunctiva, the entire lateral and inferior forniceal conjunctiva, and most of the inferior tarsal conjunctiva (see figure 1). Gonioscopy showed no involvement of the angles. Fundus examination was normal. Examination of the left eye was unremarkable. There was no lymphadenopathy.

Anterior segment optical coherence tomography (OCT) (Casia 2, Tomey, Aichi, Japan) showed there was no invasion of the globe. An incisional biopsy was

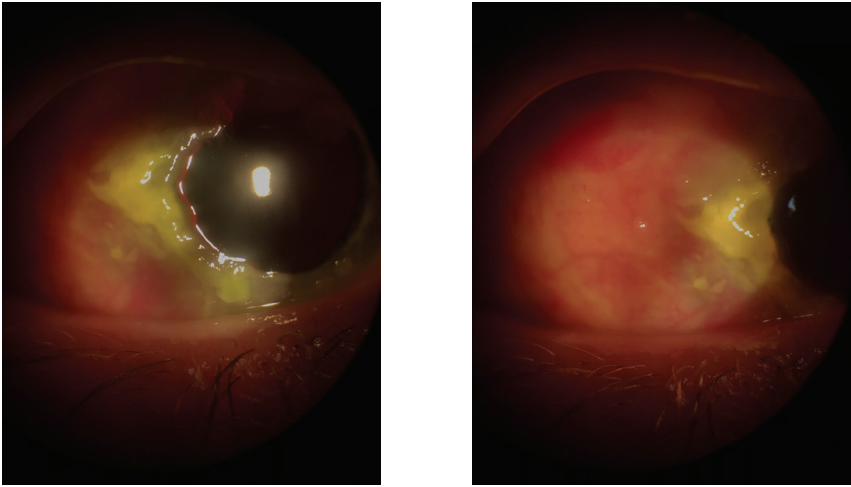


Fig. 1. Anterior segment photos of the right eye showing (*left*) conjunctival SCC involving the limbus and (*right*) conjunctival SCC involving a large section of the bulbar conjunctiva.

performed, and the biopsied section showed a poorly differentiated conjunctival squamous cell carcinoma (SCC). A magnetic resonance imaging (MRI) scan of the orbits, brain, and neck was performed which showed no evidence of orbital invasion, lymph node involvement or cerebral metastasis. This lesion was classified as T3, N0, M0 according to the American Joint Committee on cancer classification of ocular surface squamous neoplasia.

Given the concern for possible metastasis if not treated aggressively, a decision was made to treat the lesion with primary excision rather than with topical and/or sub-conjunctival chemotherapeutic agents. Due to the absence of orbital extension, exenteration was considered unnecessary. The corneal team performed excision of the lesion from globe with 4 mm margins. Double freeze-thaw cryotherapy was applied to the limbus and conjunctival edge. An amniotic membrane transplant was applied to the area of excision and fixed with fibrin glue. The oculoplastics team performed excision of the lesion from the forniceal and palpebral conjunctiva. A buccal mucosa graft was harvested and sutured to the area of excision. Postoperatively, topical mitomycin C 0.04% four times a day for three weekly cycles, with 1 week without drops in between cycles was prescribed. The patient reported good adherence to treatment.

Two months postoperatively, the patient was troubled by severe eye discomfort, poor vision, and diplopia. Examination of the affected eye showed that CDVA was count fingers at 50 cm. No evidence of residual disease was present although there was significant limbal stem cell deficiency as evidenced by pannus, which extended to involve the central cornea. There was severe dry eye with grade 4 Oxford ocular surface staining. Extraocular motility was severely impaired (-3 adduction, -2

abduction, -1 elevation, -1 depression) due to symblepharon which extended from 3 o'clock to 12 o'clock, resulting in significant forniceal shortening. These symptoms and signs have persisted until the last review 6 months following excision of the lesion. Plans for future ocular surface reconstruction include: upper and lower forniceal reconstruction with buccal mucosa graft, *ex vivo* limbal stem cell transplantation, and possible corneal transplantation depending on the extent of corneal scarring and irregularity following the limbal stem cell transplant.

Discussion

Conjunctival SCC is a conjunctival tumour arising from the epithelial layer that breaches the epithelial basement membrane and invades the underlying stroma.¹ This tumour has the ability to invade the lamella of the cornea and sclera to invade the anterior chamber of the eye. Furthermore, conjunctival SCC can also penetrate the orbital septum to invade the orbit, sinuses, and brain.² In rare cases, conjunctival SCC can gain access to blood vessels and lymphatics, resulting in local and distant metastasis, and even death.³

Several treatment modalities for conjunctival SCC are described in the literature. The most commonly reported treatment is wide-margin excision with or without cryotherapy.⁴ Other treatments include topical or perilesional chemotherapy,⁵ external beam radiotherapy,⁶ plaque radiotherapy,⁷ and orbital exenteration.⁸

An important challenge facing the clinician treating extensive conjunctival SCC is achieving disease eradication whilst minimising treatment-induced morbidity. In this case, priority was given to treating the disease to ensure no further local and metastatic spread. An alternative treatment course considered was to treat with topical interferon α -2b in the hope of reducing the size of the lesion (chemo-reduction), thus allowing a smaller and less invasive excision. However, the treating team was concerned regarding the possibility of local invasion and metastasis occurring during the period of chemo-reduction.

Ultimately, the treatment resulted in significant ocular morbidity, including limbal stem cell deficiency, severe dry eye, ophthalmoplegia, and diplopia. Given the significant iatrogenic morbidity, the question arises whether the treatment undertaken was justified to minimise the risk of metastasis. Published data of conjunctival SCC shows that rates of metastatic disease following treatment for conjunctival SCC ranges from 0 to 18%, depending on the series, with rates of death ranging from 1% to 12%.^{2,9,10} The average follow-up period in these studies ranges from 24 to 56 months. Sites of metastatic disease include regional lymph nodes, lungs, and brain.

The authors considered the option of treating with topical or perilesional chemotherapeutic agents. However, this was decided against as the evidence regarding the longer-term outcomes of local chemotherapy for conjunctival SCC is limited.

Arguably, the best evidence comes from a case series of 18 eyes published by Kim *et al.*, which showed excellent outcomes in eyes treated with topical and/or injected interferon α -2b, with no cases of metastasis or death.⁵ However, this case series' median follow-up period was only 11 months and metastatic disease may not manifest until several years later.

In conclusion, this case illustrates the difficult issues that arise when treating conjunctival SCC as the clinician attempts to balance disease eradication and treatment-induced morbidity. There is no clear consensus regarding the appropriate treatment of such cases and certainly more research is needed to clarify the most effective treatment modalities for conjunctival SCC.

References

1. Lee GA, Hirst LW. Ocular surface squamous neoplasia. *Surv Ophthalmol.* 1995;39(6):429-450.
2. Miller CV, Wolf A, Klingenstein A, et al. Clinical outcome of advanced squamous cell carcinoma of the conjunctiva. *Eye (Lond).* 2014;28(8):962-967.
3. Shields CL, Shields JA. Tumors of the conjunctiva and cornea. *Surv Ophthalmol.* 2004;49(1):3-24.
4. Shields JA, Shields CL, De Potter P. Surgical management of conjunctival tumors. The 1994 Lynn B. McMahan Lecture. *Arch Ophthalmol.* 1997;115(6):808-815.
5. Kim HJ, Shields CL, Shah SU, Kaliki S, Lally SE. Giant ocular surface squamous neoplasia managed with interferon alpha-2b as immunotherapy or immunoreduction. *Ophthalmology.* 2012;119(5):938-944.
6. Lommatzsch P. Beta-ray treatment of malignant epithelial tumors of the conjunctiva. *Am J Ophthalmol.* 1976;81(2):198-206.
7. Arepalli S, Kaliki S, Shields CL, Emrich J, Komarnicky L, Shields JA. Plaque radiotherapy in the management of scleral-invasive conjunctival squamous cell carcinoma: an analysis of 15 eyes. *JAMA Ophthalmol.* 2014;132(6):691-696.
8. McKelvie PA, Daniell M, McNab A, Loughnan M, Santamaria JD. Squamous cell carcinoma of the conjunctiva: a series of 26 cases. *Br J Ophthalmol.* 2002;86(2):168-173.
9. Chauhan S, Sen S, Sharma A, et al. American Joint Committee on Cancer Staging and clinicopathological high-risk predictors of ocular surface squamous neoplasia: a study from a tertiary eye center in India. *Arch Pathol Lab Med.* 2014;138(11):1488-1494.
10. Tunc M, Char DH, Crawford B, Miller T. Intraepithelial and invasive squamous cell carcinoma of the conjunctiva: analysis of 60 cases. *Br J Ophthalmol.* 1999;83(1):98-103.